



# Therapeutic implications of narrow or positive surgical margins in head and neck tumors

Marta Biedka-Paluch<sup>1,2</sup> , Patryk Biedka<sup>3</sup>, Janusz Winięcki<sup>1,2</sup> 

1 Radiotherapy Department, Oncology Center – Prof. Franciszek Łukaszczyk Memorial Hospital, Bydgoszcz, Poland

2 Chair and Clinic of Oncology and Brachytherapy, Ludwik Rydygier Collegium Medicum in Bydgoszcz, Nicolaus Copernicus University in Toruń, Poland

3 Academy of Applied Medical and Social Sciences, Elbląg, Poland

## Publishing info

Received: 2023-12-25

Accepted: 2024-10-23

Online first: 2024-11-20

## Keywords:

surgery  
radiotherapy  
head and neck cancers  
narrow/positive margins.

## User license:

This work is licensed under a Creative Commons License: CC-BY-NC.



Original version of this paper is available here



## Abstract

**Introduction:** The treatment of squamous cell carcinomas of the head and neck region involves a multidisciplinary approach that combines surgery, radiotherapy and chemotherapy.

**Aim:** The aim of this article is to discuss the therapeutic implications of narrow or positive surgical margins in head and neck cancers.

**Material and methods:** The article was written based on the analysis of the literature on the subject.

**Results and discussion:** Surgical resection is an important part of a approach to treatment and the adequacy of resection during surgery is determined by the margin status. A margin greater than 5 mm is considered free, less than 5 mm - narrow, and less than one mm is considered positive. For proper planning of radiotherapy, i.e. adequate selection of areas and doses, the following are necessary: imaging, endoscopy, pathology report. It should also be remembered that the lack of important information from the treatment and the fear of making a geographical error and/or not matching the dose to the actual stage of the disease and the status of the margins; affects the decision of the radiotherapist who will escalate the dose, which may lead to long-term tissue damage with loss of their function and significantly affect the quality of life of these patients.

**Conclusions:** Before initiating treatment, each patient should undergo analysis in multidisciplinary consultations to tailor the optimal therapeutic decision to the stage of the disease and any coexisting conditions. Patients with advanced disease and/or challenging localization and/or rare disease diagnoses should be treated in highly specialized centers where close collaboration between facilities is essential.

## Corresponding author:

Marta Biedka-Paluch, Radiotherapy Department, Oncology Center – Prof. Franciszek Łukaszczyk Memorial Hospital, Romanowskiej 2, 85-796 Bydgoszcz, Poland.

Tel. +48 605 478 745.

**E-mail:** [biedkam@co.bydgoszcz.pl](mailto:biedkam@co.bydgoszcz.pl)

## 1. INTRODUCTION

Head and neck squamous cell carcinomas (HNSCC) are among the most challenging malignancies to treat due to their complex anatomy and the vital functions they affect. The primary treatment modality for HNSCC is surgical resection, aiming to achieve clear margins. Which reduce the risk of local recurrence and improve survival outcomes. The concept of surgical margins is well-established in the literature, with margins greater than 5 mm generally considered clear, less than 5 mm termed narrow, and margins less than 1 mm classified as positive.<sup>1</sup> The status of these margins is a critical determinant in subsequent therapeutic decisions, particularly in the planning of adjuvant radiotherapy (RTH) and, to a lesser extent, chemotherapy (CTH). Numerous studies have demonstrated that patients with narrow or positive margins are at a significantly higher risk of local recurrence and poorer survival outcomes. This has led to the common practice of using adjuvant radiotherapy to manage residual microscopic disease in case of these patients. Advances in radiotherapy techniques, such as intensity-modulated radiotherapy (IMRT) and proton therapy, have allowed for more precise targeting of tumor tissues, while minimizing damage to surrounding healthy structures. These advancements have the potential to improve local control and reduce treatment-related morbidity in patients with challenging margin statuses.<sup>3</sup>

Despite the established importance of surgical margin status, there remains significant variability in how margins are defined, assessed, and managed across different institutions. The lack of standardized criteria for what constitutes a clear, narrow, or positive margin leads to inconsistencies in clinical practice, particularly in the planning of adjuvant therapies. Furthermore, while it is known that narrow and positive margins increase the risk of local recurrence, the precise impact of margin status on the outcomes of modern RTH techniques remains underexplored. There is limited data on how different margin statuses should influence the choice of radiotherapy modality, dose escalation, and the inclusion of surrounding tissues in the treatment field.<sup>4</sup>

The current literature provides limited guidance on the integration of surgical margin status with advanced RTH planning. Specifically, there is a gap in understanding how the variability in margin definitions and assessment affects the decision-making process in adjuvant RTH, and how these decisions, in turn, influence patient outcomes. Additionally, the implications of adopting more precise RTH techniques, such as IMRT and proton therapy, in the context of narrow or positive margins have not been thoroughly investigated.<sup>1,3,4</sup>

## 2. AIM

The aim of this work is to discuss narrow or positive surgical margins in HNSCC as a critical factor. To ensure coordinated and integrated multidisciplinary evaluation and treatment by all specialists involved in patient care before the initiation of any therapy, with particular emphasis on adjuvant RTH.

## 3. MATERIAL AND METHODS

A comprehensive literature review was conducted to gather relevant studies that examine the therapeutic implications of narrow and positive surgical margins in HNSCC. The search was performed using several electronic databases, including PubMed and MEDLINE, covering publications from April 1993 to April 2021. Keywords used in the search included 'narrow surgical margins,' 'positive surgical margins,' 'head and neck cancers,' 'radiotherapy,' 'surgical oncology,' and 'adjuvant therapy.' Both retrospective and prospective studies, as well as systematic reviews and meta-analyses, were included in the search criteria.

## 4. RESULTS AND DISCUSSION

### 4.1. SURGICAL REPORTS

Surgical resection is a crucial component of a multimodal approach to treating head and neck tumors. The adequacy of surgical resection is determined by the margin status, which is the measured distance between the tumor edge and the margins of the specimen cut. A margin greater than 5 mm is considered clear (R0), less than 5 mm is narrow, and less than one mm is labeled as positive (R+), (Table 1). However, this principle does not apply uniformly to all head and neck tumors and can affect the final histopathological findings.<sup>2</sup>

In tongue cancer, a resection margin of 1–2 cm is recommended to achieve a microscopically clear margin of around 5 mm, which can pose a significant

**Table 1. Definition of margins and indication for adjuvant RTH.**

R feature	Margins	Adjuvant RTH	RTH total dose, Gy
R negative (R-), (R0)	>5 mm	-/+	60
R narrow (R0/1)	1–5 mm	+/-	66
R positive (R+)	<1 mm	+	70
R1	Positive microscopic	+	70
R2	Positive macroscopic	+	70

challenge for the surgeon. For tumors involving the mucous membrane of the cheek, intraoperative examination suggests resection margins of at least 1 cm to ultimately achieve a microscopic margin of 5 mm. The anatomy of cheek tissue and its contractility post-resection may make it impossible to achieve such a margin. During the removal of a salivary gland while preserving the facial nerve, achieving a measurable microscopic thickness of 5 mm may not be possible.<sup>5</sup>

It is crucial to consider factors influencing the success of surgery in patients, as effective multidisciplinary treatment often starts with a successful surgical resection. Although the link between positive final margins and poorer survival is well-known, it may actually reflect aggressive, infiltrative tumor biology, making it challenging to accurately assess the true tumor margins through visual inspection or manual palpation. Positive frozen margins may thus indicate lymphatic spread, broader areas of compromised mucosa, or tumor development in the tissue surrounding the tumor. In such cases, in addition to the isolated tumor, there may be widespread mucosal disease, predisposing to disease recurrence and confirming the hypothesis of locally aggressive tumor biology without an increased likelihood of distant metastases.<sup>6</sup>

Additionally, the definition of narrow and/or positive margins is interpreted differently, as demonstrated by Meier et al. study.<sup>7</sup> In this study, a questionnaire was conducted among members of the American Head and Neck Society to investigate how surgeons define margins and how they use frozen sections to assess margins. The authors received responses from 476 individuals out of 1500 respondents. Most surgeons considered a margin negative when it measured above 5 mm in microscopic evaluation. A margin containing in situ cancer was mostly regarded as positive, while most did not consider a margin containing dysplasia as positive. When initial frozen section margins were positive, and subsequent resection resulted in negative frozen section margins, 90% of respondents considered the margins negative. It's important to note that reports often lack information on initial positive margins and their extent, which can impact decisions about adjuvant treatment. The authors also emphasized that most surgeons do not take a frozen section sample from the main specimen, which may lead to errors in identifying a positive margin. Additionally, nearly half of the operators use wider margins during the resection of tumors treated with neoadjuvant therapy. In the case of recurrent or residual tumors previously treated with CTH, most resect to the margin from before treatment. In the conclusions, the authors high-

light the lack of uniform criteria for defining a clear surgical margin among practicing surgeons specializing in head and neck tumors.<sup>7</sup>

Another interesting study is by Jones,<sup>8</sup> where a group of 352 patients with HNSCC underwent primary radical RTH, followed by surgical resection due to disease recurrence. In the obtained results, a total of 303 (86%) patients had preserved margins, and 49 (14%) had positive resection margins. The observation period was in average 12.4 years (1–32 years). The authors observed a significant association between oral cavity cancer and positive margins ( $P = 0.0292$ ). Patients with positive margin (R+), had a higher probability of developing a 'second' recurrence at the primary site (47%) compared to patients with negative margins (32%), although the differences did not reach statistical significance. There was also a higher likelihood of nodal recurrence (12%) versus patients with R(-) surgery (10%), although the result was not statistically significant. The authors observed that in over one-third of patients with positive margins, the disease-free survival reached 5 years. This was influenced by the type of surgery performed and the use of diathermy, which may have eradicated residual tumor cells in the operated tissue. The creation of scar tissue following surgery could have contributed to the outcome by impeding the function and further growth of tumor cells.

However, the obtained result could also be influenced by an acute inflammatory response during the wound healing process after surgery, which could destroy tumor cells.<sup>6</sup> Importantly, studies show that a significant percentage of procedures have questionable margins. In a retrospective study by Pfreundner,<sup>9</sup> where 257 patients were treated, including 40 with T1, 80 with T2, 53 with T3, and 84 with T4 tumors, with nodal involvement in 181 cases, the entire group obtained 64 tumor-free resections (>3 mm), 66 patients had narrow resection margins (<3 mm), 101 patients had R1 resections, and 26 patients had R2 resections, totaling 193 patients (75%) with positive or narrow margins in the entire group. Therefore, the scale of the problem is significant and should not be underestimated.<sup>9</sup>

It is worth considering whether initial positive margins impact the survival of patients with squamous cell carcinoma who undergo total laryngectomy and have negative final margins. This question was posed by Tassone et al.<sup>6</sup> in a retrospective cohort study of 237 patients from 2008 to 2016. Margins were considered positive, if they contained invasive cancer, in situ cancer, or severe dysplasia. In the analysis, 92% were male with a mean age of 63.9 (range 30–92 years). In the multifactorial analysis, salvage laryngectomy alone was signifi-

cantly associated with worse disease-free survival (hazard ratio – HR, 3.35; 95%CI: 1.76–6.36). Among 127 patients with primary total laryngectomy and features such as N(+), LVSI(+), ECE(+), and R1, results were associated with worse disease-free survival. However, only initial positive margins were significantly associated with worse disease-free survival in multifactorial analysis (HR 5.01; 95%CI: 1.55–16.2), and the addition of adjuvant radiotherapy improved these results. The authors concluded that initial positive margins were associated with worse asymptomatic survival among patients undergoing primary total laryngectomy despite negative margins in the final pathological examination. This discovery may indicate aggressive tumor behavior in the context of primary laryngeal squamous cell carcinoma and may influence further therapeutic decisions.<sup>6</sup>

In this context, the status of the frozen margin can be considered an indirect risk factor and not as strongly associated with poor prognosis as incomplete resection resulting from positive final margins. Although positive final margins are generally accepted as an indication for RTH, with or without CTH, further research on the status of frozen margins should be conducted before incorporating them into decisions regarding adjuvant treatment.

#### 4.2. HISTOPATHOLOGICAL REPORTS

The precise anatomical orientation of the excised specimen and identification of all margins constitute an integral part of histopathological assessment. Methods employed for margin identification before and after processing include the use of dyes/pigments, cutting techniques, and the placement of clips or stitches to reduce identification errors.<sup>10</sup> In RTH planning, concerns about geographic errors also arise. In other tumor locations, it happens that surgeons mark doubtful or R1/2 margins to indicate their exact location to the radiation oncologist. It should be considered whether this is also possible in head and neck tumors.

Histopathological reporting protocols emphasize the lack of molecular and genetic studies as a standard for margin assessment. The 8th edition of the *American Joint Committee on Cancer Staging Manual* indicates that even if resection margins are deemed tumor-free, the local recurrence rate ranges from 10% to 30%. The underlying causes are attributed to the genetic predisposition of the tumor, with 20%–60% of such cases detected through molecular and genetic analyses that remained undetected by standard histopathology.<sup>11</sup>

Furthermore, disparities are observed between margins measured by surgeons and those analyzed by pathologists post-resection. Various factors influence

this situation, including the elasticity of the mucosal membrane, tissue contraction post-resection, and its pathological processing. To achieve a pathological margin greater than 5 mm, the clinical margin of resection should be greater than 10 mm for mucosal and deep margins and 10 mm for bone margins, which can be challenging or even impossible to achieve in certain head and neck tumor locations.<sup>10</sup>

In the study by Black et al.<sup>12</sup>, which focused on the evaluation of frozen sections allowing correction of positive margins before surgical closure and reconstruction compared to the final pathological report, 200 pathologists were surveyed about the current process of assessing margin specimens at their institutions. Respondents reported that most surgeons send small tissue fragments from the surgical defect, receive small, unoriented tissue fragments, and often need to resample all or most margins to obtain the final pathological report without anatomical orientation from the surgeon. Additionally, pathologists sometimes do not sample margins. In their conclusions, the authors emphasize that there may be excessive or insufficient sampling of margins, and the accuracy of the final pathological report may be compromised. They also stress that there is currently no consensus on the best way to submit tissue for frozen section margin assessment in head and neck tumor resections.<sup>12</sup>

An interesting study by Chang et al.<sup>13</sup> analyzed 126 patients with stage pT1-2 pN0 squamous cell carcinoma of the tongue and oral cavity. Patients were divided into 3 groups: (1) where samples were taken from glossectomy; (2) where margin revisions were performed on glossectomy; and (3) where margins were mainly taken from the tumor bed. The results showed that the probability of local progression-free survival after 3 years was 0.90, 0.76, and 0.73 ( $P = 0.0389$ ) in groups 1, 2, and 3, respectively. Positive glossectomy margins had a 2.5-times higher relative risk (95%CI: 1–6.3) for local recurrence. The authors also demonstrated a 33% reduction in the risk of local recurrence with an increase in margin width by 1 mm ( $P = 0.0271$ ).

In summary, the state of glossectomy margins, rather than margins from the tumor bed, was prognostically significant. Relying on margins from the tumor bed appears to be associated with poorer local control, possibly due to a narrower initial resection.<sup>13</sup>

On the practical side, it is essential to emphasize that histopathological protocols lack information about primary margins and their possible extension, which can impact qualification for adjuvant radiotherapy. On the other hand, a negative resection margin does not guarantee the absence of residual tumor

within unresected tissues. Although margins are always carefully examined by pathologists, they form a three-dimensional structure, and consequently, cancer cells may be missed during the preparation of samples for histopathological examination. This may explain the erroneously high number of patients with ostensibly negative margin results who experience primary disease recurrence, which is, in fact, disease progression.<sup>8,14</sup>

#### 4.3. PRACTICAL DISCUSSION ON THE IMPACT OF NON-RADICAL SURGERY ON THE PLANNING AND IMPLEMENTATION OF POSTOPERATIVE RADIOTHERAPY

Recent advancements in radiotherapy, particularly IMRT and proton therapy, have allowed for more precise targeting of tumor tissues, while sparing surrounding healthy structures. These techniques may offer improved local control for patients with narrow or positive surgical margins, potentially reducing the need for dose escalation and its associated toxicities.

Postoperative RTH can enhance locoregional control (LC) in patients with HNSCC who have positive resection margins.<sup>15</sup> However, the primary goal should always be to achieve an R0 resection, where no adjuvant RT or CHT is needed. To ensure this, a comprehensive diagnostic workup should be performed before treatment qualification to accurately stage the cancer using the TNM classification. The tumor's location and stage can significantly impact therapeutic decisions. If surgery with narrow or positive margins is anticipated, additional preoperative measures should be considered, a more extensive surgical approach proposed, or a shift to primary RTH ± CHT should be evaluated.<sup>15</sup>

In the study by Lang et al., 162 patients were analyzed. Among them, 77 patients (47.5%) had involved margins (<1 mm), 22 patients (13.6%) had close margins (≤5 mm), and only 63 patients (38.9%) had tumor-free margins (>5 mm). A surgical margin of up to 5 mm was identified as a significant predictor of poorer local control (HR 2.6, 95%CI: 1.2; 6.1). However, in this study, it did not significantly impact overall survival (OS) (HR 1.2, 95%CI: 0.7; 1.9) or progression-free survival (PFS) (HR 1.2, 95%CI: 0.7; 2.0). In conclusion, over 60% of the patients in this study had narrow or positive margins and required adjuvant treatment, a pattern consistent with findings from other scientific reports.<sup>15</sup>

In the study by Soliman et al., data from the National Cancer Database were analyzed for adult patients with HPV(+) early-stage oral cancer who underwent surgery between 2010 and 2017. Special attention was given to indications for adjuvant postoperative RTH. Of the 15,036 patients who met the inclusion criteria,

55.7% had at least one factor indicating a worsened prognosis, and therefore, adjuvant treatment was recommended. Positive margins were found in 48.2% of cases, and margin status was unknown in 4.3%, meaning that over 50% of patients underwent nonradical surgery. Statistical analysis confirmed that positive margins were associated with worse OS (HR = 1.58,  $P = 0.002$ ). The median 3-year OS was 92.0% for patients who received adjuvant RTH, compared to 84.2% for those who did not ( $P < 0.001$ ,  $n = 1678$ ).<sup>16</sup>

Notably, the authors emphasized that 13% of patients with HPV(+) oral cancer did not receive adjuvant RTH, with this percentage increasing from 10% in 2010 to 17% in 2017. This highlights the importance of ensuring that patients are adequately staged and treated to avoid incomplete treatments.<sup>16</sup>

As Bernier pointed out, the selection of primary treatment in the form of surgery may require patients to undergo not just one, but three types of oncological treatments, including surgery, RTH, and potentially CHT. This underscores the need for a broader panel of diagnostic tests to properly stage the disease. It also highlights the importance of a prospective interdisciplinary tumor board meeting to determine the best primary oncological treatment, aiming to avoid the necessity for adjuvant or salvage therapy.<sup>17</sup>

After surgery, there is a significant interruption in vascularization and scarring in the postoperative cavity, where reduced oxygenation of cells occurs at the resection margin. Additionally, hypoxic cancer cells in vitro/in vivo are more resistant to radiation than well-oxygenated cells. Increasing the radiation dose may enhance local control but at the expense of side effects. Therefore, our goal should be an R0 operation with no indications for adjuvant RTH or radiochemotherapy (RTH+CHT). In cases where we anticipate an R1 operation and/or ECE (+), alternative preparations for surgery and/or a different type of surgery should be considered to avoid the need for adjuvant treatment or explore alternative therapeutic decisions, such as switching to RTH+CHT as primary treatment where feasible, or considering neoadjuvant treatment to reduce tumor size and extent before surgery as primary treatment.<sup>5</sup>

Indications for RTH include two or more risk factors influencing disease recurrence, among others: narrow or positive margins, ≥2 positive lymph nodes (Table 2). A treatment delay exceeding 6 weeks is also an indication for RTH, often influenced by the extent of the procedure and/or postoperative complications (Table 3). Therefore, any patient with doubtful or positive margins a priori must undergo adjuvant treatment.<sup>18-21</sup>

**Table 2. Indications for postoperative radiotherapy.**

Risk factors*
Primary cancer of the oral cavity
Narrow or positive R0/1, R1, R2 margins
Perineural invasion (PNI+)
≥ 2 positive lymph nodes, with the largest node > 3 cm
Extracapsular extension of the tumor beyond the lymph node (ECE+)
Vascular or lymphatic space invasion (LVSI+)
High-grade malignancy (G3)
Depth of infiltration (DOI)*
Any T3 or T4 tumor according to TNM classification**
Delayed treatment beyond 6 weeks

Comments: \* Two or more risk factor increase the likelihood of recurrence; \*\* According to AJCC 8th edition.

**Table 3. Delay in treatment as an indication for radiotherapy.**

A delay in treatment beyond 6 weeks is always an indication for radiotherapy or
Delayed tissue healing
Need for tracheostomy placement
Tracheostomy infection
Need for PEG tube/gastrostomy placement
Need for postoperative imaging
Verification of R1/R2 resections (PET/CT scan)
Diagnosis of lung nodules
Suspicion of a second tumor and/or metastasis

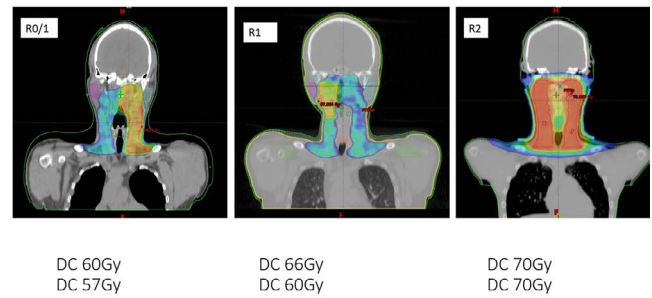
To ensure proper planning of RTH, i.e., the correct selection of areas and doses, several elements are crucial: preoperative imaging, endoscopic examination, surgical description of the procedure, a comprehensive pathological report, and 'important information from the operator and/or the attending physician.'

These data play a decisive role in qualifying for RTH and also impact the total radiation dose, the volumes/size of areas irradiated at high doses, the volumes/size of areas irradiated in lymph node groups receiving high doses, and the inclusion of lymph node groups in the elective radiation field.

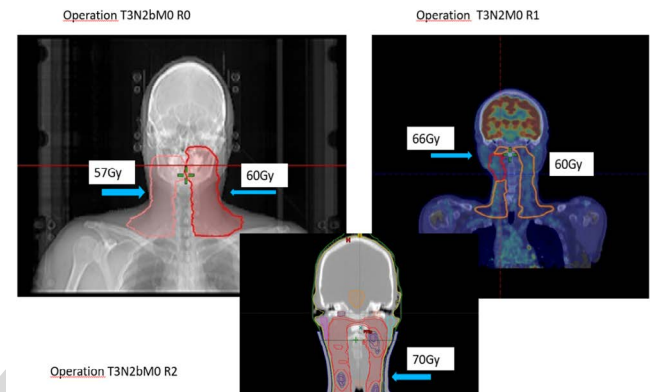
Guidelines recommend that patients with R1 and R2 resections be treated with doses greater than 68 Gy (2 Gy per fraction, 5 fractions per week), and those with narrow margins (<3 mm) above 66 Gy (Table 1). Studies show that the application of RTH is a strongly favorable variable for local control and adjusted risk survival in the case of ECE+ and/or R1 procedures (Table 2).<sup>22</sup> However, it should be noted that these patients also experience a higher percentage of severe complications after radiation therapy (Figures 1 and 2).

It is essential to consider the risk of geographical error and/or failure to adjust the dose to the actual stage of the disease and margin status. It should be emphasized that radiation oncologist will escalate the dose for each patient with unknown margin status (Rx) and with narrow/positive margin.

It is important to note that RTH or RTH+CTH leads to long-term tissue damage with a loss of function, significantly impacting the quality of life in case of these



**Figure 1. Patients with the same diagnosis and stage of advancement differing in the status of margins – impact on the total dose of radiotherapy and the volume of tissues subjected to irradiation.**



**Figure 2. Patients with the same diagnosis and stage of disease according TNM classification – impact on the total dose of radiotherapy and the volume of tissues subjected to irradiation.**

patients. Physicians planning RTH are mindful of its side effects and aim to avoid over-treatment. However, when there is concern about leaving the patient without sufficient supplementary treatment, particularly when the full extent of the disease's progression is unclear before or after surgery, they may expand the areas subjected to radiation. Additionally, the radiation dose may be increased to ensure thorough treatment.<sup>12</sup>

## 5. CONCLUSIONS

Tumors of the head and neck region pose a significant challenge for the attending physician and require a multidisciplinary approach that combines surgery, RTH, and systemic therapy. Therefore, before initiating treatment, each patient should undergo analysis in multidisciplinary consultations prospectively, to tailor the optimal therapeutic decision to the stage of the disease and any coexisting conditions.

A proposed decision-making pathway could include:

- (1) Thorough re-evaluation of the surgical margins through both frozen section and permanent pathology,
- (2) Consideration of neoadjuvant therapy in cases where a positive margin is anticipated,

(3) Integration of advanced RTH techniques to minimize the risk of recurrence while reducing treatment-related morbidity.

Furthermore, patients with advanced disease and/or challenging localization, should be treated in highly specialized centers where close collaboration between facilities is essential. This collaboration ensures that both diagnostics, surgical and histopathological reports are as comprehensive as possible, containing all necessary information needed for the prompt initiation of supplementary treatment, if required, and adjusted to the patient's actual clinical situation.

#### CONFLICT OF INTEREST

None declared.

#### FUNDING

None declared.

#### REFERENCES

- 1 Rosenberg A, Vokes E. Optimizing treatment de-escalation in head and neck cancer: Current and future perspectives. *Oncologist*. 2021;26(1):40–48. <https://doi.org/10.1634/theoncologist.2020-0303>.
- 2 Vidhyadharan S, Augustine I, Kudpaje A, Iyer S, Thankappan K. Site-wise differences in adequacy of the surgical resection margins in head and neck cancers. *Indian J Surg Oncol*. 2014;5(3):227–231. <https://doi.org/10.1007/s13193-014-0341-4>.
- 3 Zhong S, Zuo W. Treatment strategies for malignancies of the external auditory canal. *Curr Treat Options Oncol*. 2022;23(1):43–53. <https://doi.org/10.1007/s11864-021-00931-3>.
- 4 Gupta A, Wong KH, Newbold K, Bhide S, Nutting C, Harrington KJ. Early-stage glottic squamous cell carcinoma in the era of image-guided radiotherapy. *Front Oncol*. 2021;11:753908. <https://doi.org/10.3389/fonc.2021.753908>.
- 5 Mansour N, Backes C, Becker C, Hofauer B, Knopf A. Clear resection margins to avoid escalation of adjuvant therapy in oropharyngeal squamous cell carcinoma. *HNO*. 2021;69(4):256–262. <https://doi.org/10.1007/s00106-020-00932-y>.
- 6 Tassone P, Savard C, Topf M, et al. Association of positive initial margins with survival among patients with squamous cell carcinoma treated with total laryngectomy. *JAMA Otolaryngol Head Neck Surg*. 2018;144(11):1030–1036. <https://doi.org/10.1001/jamaoto.2018.1095>.
- 7 Meier J, Oliver D, Varvares M. Surgical margin determination in head and neck oncology: current clinical practice. The results of an International American Head and Neck Society Member Survey. *Head Neck*. 2005;27(11):952–958. <https://doi.org/10.1002/hed.20269>.
- 8 Jones A, Hanafi Z, Nadapalan V, Roland N, Kinsella A, Helliwell T. Do positive resection margins after ablative surgery for head and neck cancer adversely affect prognosis? A study of 352 patients with recurrent carcinoma following radiotherapy treated by salvage surgery. *Br J Cancer*. 1996;74(1):128–132. <https://doi.org/10.1038/bjc.1996.327>.
- 9 Pfreundner L, Willner J, Marx A, Hoppe F, Beckmann G, Flentje M. The influence of the radicality of resection and dose of postoperative radiation therapy on local control and survival in carcinomas of the upper aerodigestive tract. *Int J Radiat Oncol Biol Phys*. 2000;47(5):1287–1297. [https://doi.org/10.1016/s0360-3016\(00\)00514-9](https://doi.org/10.1016/s0360-3016(00)00514-9).
- 10 Kamat M, Das Rai B, Puranik R, Datar U. A comprehensive review of surgical margin in oral squamous cell carcinoma highlighting the significance of tumor free surgical margins. *J Cancer Res Ther*. 2019;15(3):449–454. [https://doi.org/10.4103/jcrt.JCRT\\_273\\_17](https://doi.org/10.4103/jcrt.JCRT_273_17).
- 11 Maghami E, Koyfman S, Weiss J. Personalizing postoperative treatment of head and neck. *Am Soc Clin Oncol Educ Book*. 2018;38:515–522. [https://doi.org/10.1200/edbk\\_201087](https://doi.org/10.1200/edbk_201087).
- 12 Black C, Marotti J, Zarovnyaya E, Paydarfar J. Critical evaluation of frozen section margins in head and neck cancer resections. *Cancer*. 2006;107(12):2792–2800. <https://doi.org/10.1002/cncr.22347>.
- 13 Chang A, Kim S, Duvvuri U, et al. Early squamous cell carcinoma of the oral tongue: Comparing margins obtained from the glossectomy specimen to margins from the tumor bed. *Oral Oncol*. 2013;49(11):1077–1082. <https://doi.org/10.1016/j.oraloncology.2013.07.013>.
- 14 Saraniti C, Speciale R, Gallina S, Salvago P. Prognostic role of resection margin in open oncologic laryngeal surgery: survival analysis of a cohort of 139 patients affected by squamous cell carcinoma. *Braz J Otorhinolaryngol*. 2019;85(5):603–610. <https://doi.org/10.1016/j.bjorl.2018.04.012>.
- 15 Lang K, Held T, Freudlsperger C, et al. Oral cavity squamous cell carcinoma: Impact of clear margin distance on locoregional control in patients undergoing postoperative radiotherapy. *Technol Cancer Res Treat*. 2024;23:15330338241258596. <https://doi.org/10.1177/15330338241258596>.
- 16 Soliman SI, Faraji F, Pang J, Mell LK, Califano JA, Orosco RK. Adjuvant radiotherapy in surgically treated HPV-positive oropharyngeal carcinoma with ad-

- verse pathological features. *Cancers*. 2022;14:4515. <https://doi.org/10.3390/cancers14184515>.
- <sup>17</sup> Bernier J, Cooper JS, Pajak TF, et al. Defining risk levels in locally advanced head and neck cancers: a comparative analysis of concurrent postoperative radiation plus chemotherapy trials of the EORTC (#22931) and RTOG (# 9501). *Head Neck*. 2005;27(10):843–850. <https://doi.org/10.1002/hed.20279>.
- <sup>18</sup> Peters L, Goepfert H, Ang K, et al. Evaluation of the dose for postoperative radiation therapy of head and neck cancer: First report of a prospective randomized trial. *Int J Radiat Oncol Biol Phys*. 1993;26(1):3–11. [https://doi.org/10.1016/0360-3016\(93\)90167-t](https://doi.org/10.1016/0360-3016(93)90167-t).
- <sup>19</sup> Kawecki A, Nawrocki S, eds. Epithelial tumors of the head and neck organs [in Polish]. [http://onkologia.zalecenia.med.pl/pdf/zalecenia\\_PTOK\\_tom1\\_01\\_Nowotwory\\_nablonkowe\\_glowy\\_i\\_szyi\\_20140807.pdf](http://onkologia.zalecenia.med.pl/pdf/zalecenia_PTOK_tom1_01_Nowotwory_nablonkowe_glowy_i_szyi_20140807.pdf). Accessed: 2024.11.08.
- <sup>20</sup> Alterio D, De Berardinis R, Augugliaro M, D'Urso P, Volpe S, Maffini F, et al. Indication to post-operative radiotherapy for oral cavity squamous cell carcinoma: what's new in the depth of infiltration (DOI) era?. *Br J Radiol*. 2022;95(1132):20210705. <https://doi.org/10.1259/bjr.20210705>.
- <sup>21</sup> Alterio D, D'Urso P, Volpe S, et al. The impact of post-operative radiotherapy in early stage (pt1-pt-2n0m0) oral tongue squamous cell carcinoma in era of DOI. *Cancers*. 2021;13:4851. <https://doi.org/10.3390/cancers13194851>
- <sup>22</sup> Huang D, Johnson C, Schmidt-Ullrich R, Grimes M. Postoperative radiotherapy in head and neck carcinoma with extracapsular lymph node extension and/or positive resection margins: A comparative study. *Int J Radiat Oncol Biol Phys*. 1992;23(4):737–742. [https://doi.org/10.1016/0360-3016\(92\)90646-y](https://doi.org/10.1016/0360-3016(92)90646-y).

CORRECTED  
PROOF