




Differential diagnosis of palatine tonsils – clinical and histopathological perspective

Edyta Zomkowska^{1,2} , Stanisław Nitek³,
Marta Legatowicz-Koprowska⁴, Dawid Pilewski⁵, Jakub Ładyński²

- 1 Department and Clinic of Otorhinolaryngology, Head and Neck Diseases, School of Medicine, Collegium Medicum, University of Warmia and Mazury in Olsztyn, Poland
- 2 Department of Neurosurgery, Neurotraumatology and Spine Surgery, Provincial Complex Hospital, Elbląg, Poland
- 3 Department of Otorhinolaryngology, Head and Neck Diseases, Medical University of Warsaw, Warsaw, Poland
- 4 Institute of Rheumatology, Department of Pathological Anatomy, Warsaw, Poland
- 5 Collegium Medicum, Masovian Academy in Płock, Poland

Publishing info

Received: 2024-12-30
Accepted: 2024-12-31
Online first: 2024-12-31
Published: 2024-12-31

Keywords

palatine tonsils
mononucleosis
acute angina
purulent tonsillitis

User license

This work is licensed under
a Creative Commons License:
CC-BY-NC-ND.



Original version of this paper is
available here



Abstract

Introduction: The palatine tonsils are one of the most important elements of the lymphatic system in the throat. Their main function is to protect the body against microorganisms. In the differential diagnosis of palatine tonsils, there are three most common disease states: acute tonsillitis (purulent tonsillitis), detritus in the crypts and changes associated with infectious mononucleosis. The article also discusses retention cysts, which, although less common, also pose a significant diagnostic problem.

Aim: The aim of the study is to analyze the differential diagnosis of selected tonsil diseases based on the results of our own research based on clinical and microscopic examinations.

Material and methods: The study analyzed the cases of 15 patients reporting to an ENT clinic with symptoms indicating tonsillitis. The diagnosis was based on: clinical examination and photographic documentation of the tonsil image, sampling of pathological content, histopathological analysis of samples fixed in formalin and stained with the hematoxylin-eosin method.

Results and discussion: The value of histopathological diagnostics in differentiating palatine tonsil diseases may prove important in the future. It is currently not routinely used in clinical practice. In this study, histopathological tests were performed to confirm the diagnosis made at the initial stage.

Conclusions: Differential diagnosis of palatine tonsils requires a comprehensive approach, including both clinical and histopathological evaluation. A precise diagnosis enables the implementation of targeted treatment, which significantly accelerates the improvement of the patient's health condition.

Corresponding author:

Edyta Zomkowska, Department of Neurosurgery, Neurotraumatology and Spine Surgery, Provincial Integrated Hospital in Elbląg, Królewiecka 146, 82-300 Elbląg, Poland.
E-mail: ezomkowska14@gmail.com

1. INTRODUCTION

The palatine tonsils are one of the most important elements of the lymphatic system in the throat.¹ Their main function is to protect the body against microorganisms. In the differential diagnosis of palatine tonsils, there are three most common disease states: acute tonsillitis (purulent tonsillitis), detritus in the crypts and changes associated with infectious mononucleosis. The article also discusses retention cysts, which, although less common, also pose a significant diagnostic problem.

2. AIM

The aim of the study is to analyze the differential diagnosis of selected tonsil diseases based on the results of our own research based on clinical and microscopic examinations. Histopathological tests were complementary tests to the diagnostic process.

3. MATERIAL AND METHODS

The study analyzed the cases of 15 patients reporting to an ENT clinic with symptoms indicating tonsillitis. The diagnosis was based on: clinical examination and photographic documentation of the tonsil image, sampling of pathological content (pus, detritus, contents of retention cysts), histopathological analysis of samples fixed in formalin and stained with the hematoxylin-eosin (HE) method.

In 8 patients, detritus was collected from the tonsil crypts, and in 3 patients with purulent angina, pus samples were analyzed. In 2 patients with infectious mononucleosis, secretions from the surface of the tonsils were collected and analyzed. In two patients, retention cysts were incised to obtain material for testing.

4. RESULTS AND DISCUSSION

The value of histopathological diagnostics in differentiating palatine tonsil diseases may prove important in the future. It is currently not routinely used in clinical practice. In this study, histopathological tests were performed to confirm the diagnosis made at the initial stage.

In acute angina, the presence of neutrophils and bacteria is a clear marker of bacterial infection. However, in infectious mononucleosis (Figure 1), lymphocytes and atypical cells predominate, which reflects the viral nature of the disease.

Differentiating detritus from purulent exudate remains a challenge. However, despite some similarity in the macroscopic image of the palatine tonsils and

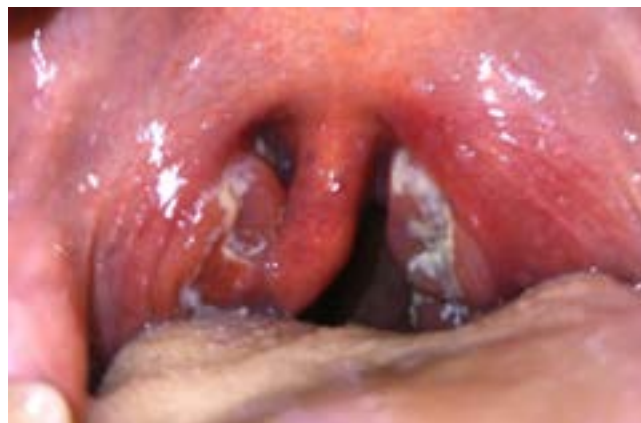

Figure 1. Infectious mononucleosis (own material).

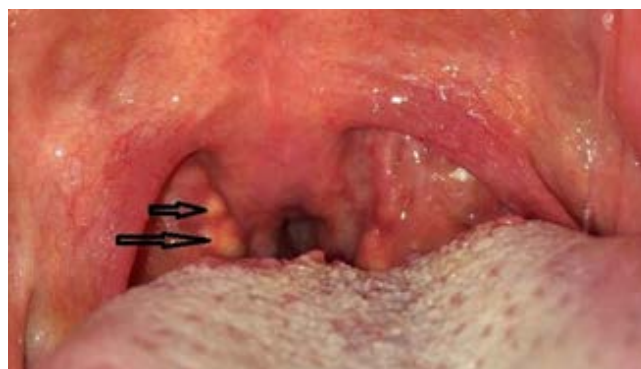

Figure 2. Retention cysts (own material).

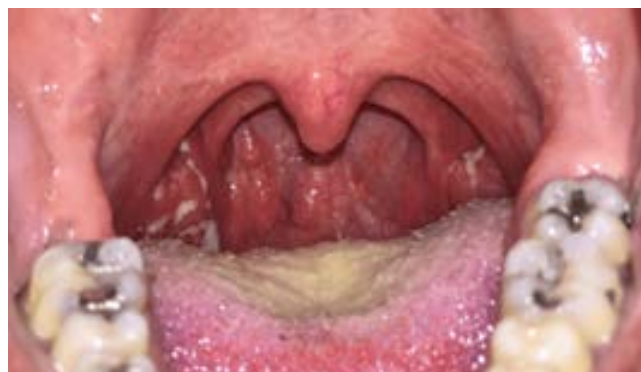

Figure 3. Purulent angina (own material).

the associated risk of confusing these two completely different disease states (Figure 2 and 3), an important clue in the differentiation is the significantly different clinical picture. A similar situation occurs in the case of retention cysts (Figure 4).

In the case of purulent angina, severe symptoms of inflammation are typical – fever, severe sore throat, usually enlarged submandibular lymph nodes. However, in the case of detritus and retention cysts, there are usually no symptoms of inflammation, or a slight pain in the tonsils or a feeling of a foreign body stuck in them. Moreover, the symptoms in purulent angina are usually acute, and in cases of detritus and retention cysts, they are chronic. Despite the macroscopic appearance of the palatine tonsils being similar at first glance, the picture of the tonsils in the course of angina

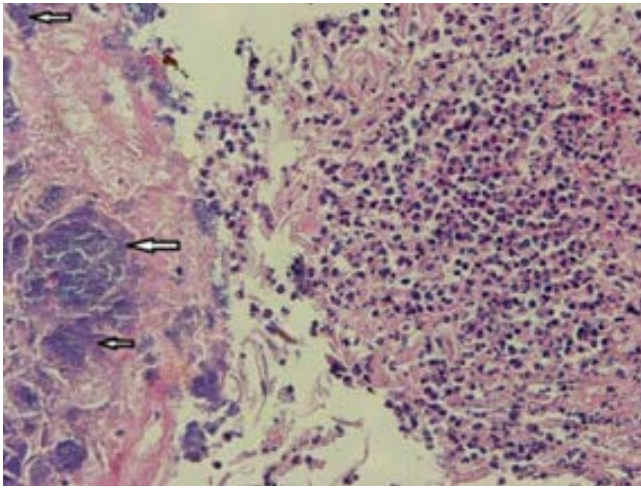


Figure 4. Purulent tonsillitis. Neutrophils (right side), arrows indicate bacterial colonies (own material).

na, detritus or retention cysts is definitely different in clinical examination.

Examination of the tonsils by pressing the anterior palatal arch with a spatula is helpful in making the correct diagnosis. In the case of detritus retention, the characteristic feature is the emergence of cheese-like white masses of detritus from the tonsil crypts, while in angina the purulent content is more liquid and bound to the surface of the tonsil. In a cyst, fluid remains inside the cyst. The use of staining techniques (e.g. HE) allows the identification of necrotic tissue and the presence of bacteria (detritus), which distinguishes these two conditions. Careful histopathological evaluation helps avoid inappropriate use of antibiotics in cases that are not related to bacterial infection. Differentiating purulent angina and infectious mononucleosis is also a major clinical challenge. Despite a completely different etiology and therefore indications for completely different treatment, the course and clinical picture of these diseases, at least in the initial phase, are usually confusingly similar. In infectious mononu-

cleosis, the lymph nodes in the neck are usually more enlarged and splenomegaly.

The diagnosis¹ of mononucleosis is usually caused by the lack of improvement in antibiotic treatment. When amoxicillin or derivatives are used in the treatment of angina, skin rash may occur. Blood count tests are also helpful - increased monocytosis and appropriate serological tests confirming EBV infection.²⁻⁴ In rare cases, there is a clinical and serological picture imitating mononucleosis, in which we are dealing with HIV infection. Untreated angina may also be a mask of leukemia – blood counts with a smear and possibly later more specialized tests are helpful here.

The treatment of individual tonsil diseases varies significantly.⁵ Purulent tonsillitis (Figure 2) requires the use of beta-lactam antibiotics, while detritus (Figure 3) can be effectively treated conservatively with gargling and improved oral hygiene.⁶ Alternatively, laser or radiosurgery cryptolysis of the tonsils is used in patients who decide to undergo such invasive treatment due to severe bad breath (halitosis) related to the retention of detritus in the tonsils. Infectious mononucleosis (Figure 1) requires symptomatic treatment, and retention cysts (Figure 4) often require surgical intervention.

In the case of acute tonsillitis (purulent tonsillitis), macroscopic examinations revealed hyperemia of the tonsils and the presence of purulent exudate in the crypts. Histopathology revealed neutrophilic infiltrates and numerous bacterial colonies. These results are consistent with previous studies that showed that acute tonsillitis is often caused by group A *streptococci*.³

In cases of infectious mononucleosis, swelling and gray-white coatings on the tonsils were macroscopically visible. Histopathological examination revealed lymphocytic infiltration and the presence of atypical lymphocytes in the tonsil tissue. Infectious mononucleosis is caused by Epstein-Barr virus infection and

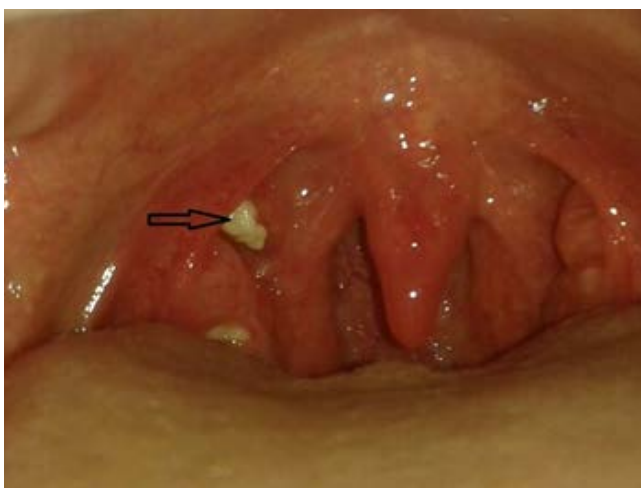

Figure 5. Detritus accumulation (own material).

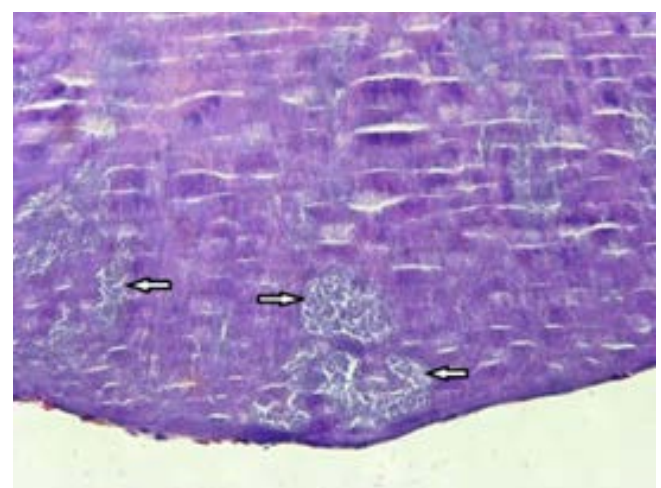


Figure 6. Detrital mass, arrows: bacterial colonies (own material).

may coexist with other bacterial infections, making diagnosis difficult.

Detritus deposited in the tonsil crypts takes the form of yellowish masses, often confused with purulent exudate. Histopathological analysis revealed areas of necrosis and epithelial cell deposits with the presence of bacterial colonies. Similar observations were presented in a study,⁵ which showed that detritus is the result of the accumulation of exfoliated epithelial cells and food debris in the tonsil crypts.

In two cases, tonsillar retention cysts were visible as clearly demarcated lesions on the surface of the tonsils. Histopathology showed the presence of epithelial cyst walls surrounding keratin masses. Retention cysts may be the result of chronic tonsillitis or blockage of the tonsil crypts.

5. CONCLUSIONS

Differential diagnosis of palatine tonsils requires a comprehensive approach, including both clinical and histopathological evaluation. A precise diagnosis enables the implementation of targeted treatment, which significantly accelerates the improvement of the patient's health condition.

CONFLICT OF INTEREST

None declared.

FUNDING

None declared.

REFERENCES

- ¹ Hurt C, Tammaro D. Diagnostic evaluation of mononucleosis-like illnesses. *Am J Med.* 2007;120(10): 911–918. <https://doi.org/10.1016/j.amjmed.2006.12.011>.
- ² Syryło A, Wojdas A, Jurkiewicz D. Bacterial flora occurring on the surface and in the parenchyma of palatine tonsils [in Polish]. *Otolaryngol Pol.* 2007;61(4):598–601. [https://doi.org/10.1016/s0030-6657\(07\)70493-6](https://doi.org/10.1016/s0030-6657(07)70493-6).
- ³ Syryło A. Tonsillitis [in Polish]. *Alergoprofil.* 2009;5(1):11-15.
- ⁴ Eid MI, Elabd SH, Erfan DM, Ziada KW, Ezzat AEM. Bacterial biofilm and its relation to cervical adenopathy, tonsillar hypertrophy and adenoid hypertrophy in chronic tonsillitis. *Pol Przegl Otolaryngol.* 2016;5(3):28–32. 10.5604/20845308.1214314.
- ⁵ McKerrow W. Tonsillitis. *Clin Evid.* 2004;12:808–813.
- ⁶ Alp H, et al. Streptococcal tonsillitis: Pathophysiology and treatment. *J Otolaryngol.* 2020.